

Musculoskeletal Ultrasonography to Diagnose Dislocated Shoulders: A Prospective Cohort



Michael A. Secko, MD, RDMS*; Lindsay Reardon, MD; Michael Gottlieb, MD; Eric J. Morley, MD; Mathew R. Lohse, MD; Henry C. Thode, Jr, PhD; Adam J. Singer, MD

*Corresponding Author. E-mail: Michael.Secko@stonybrookmedicine.edu.

Study objective: Shoulder dislocations are a common injury leading to emergency department presentations. Point-of-care ultrasonography has the potential to reduce radiation and time to diagnosis. We determine the accuracy of a novel point-of-care ultrasonographic technique to diagnose dislocated shoulders. We also investigate its accuracy to detect fractures, time to image acquisition, the optimal cutoff for the glenohumeral distance, and compare the time to diagnose dislocations from triage between point-of-care ultrasonography and radiography.

Methods: This was a multicenter prospective observational study. Ultrasonography fellows and fellowship-trained physicians enrolled a convenience sample of patients with suspected shoulder dislocation. Point-of-care ultrasonography was performed with a novel posterior approach with either a curvilinear or a linear transducer. Shoulder dislocation was confirmed with a 3-view radiograph interpreted by an independent radiologist. Sensitivity, specificity, positive predictive values, and negative predictive values were determined for point-of-care ultrasonography, with radiography as the criterion standard. Time to image acquisition, presence or absence of fracture, glenohumeral distance, sonographer confidence, and difference in time to diagnosis from triage for point-of-care ultrasonography and radiograph were also determined. A second investigator independently reviewed all images and interobserver agreement was calculated.

Results: Sixty-five patients were enrolled in the study. The sensitivity and specificity of point-of-care ultrasonography for identifying dislocations were 100% (95% confidence interval [CI] 87% to 100%) and 100% (95% CI 87% to 100%), respectively. Point-of-care ultrasonography was 92% sensitive (95% CI 60% to 99.6%) and 100% specific (95% CI 92% to 100%) for non-Hill-Sachs/Bankart's fractures of the humerus. Point-of-care ultrasonography was faster from triage than standard radiology in diagnosing dislocations (median difference 43 minutes; interquartile range [IQR] 23 to 60 minutes). The median total time required for diagnosis by point-of-care ultrasonography was 19 seconds (IQR 10 to 36 seconds). The median glenohumeral distance was -1.83 cm (IQR -1.98 to -1.41 cm) in anterior dislocations, 0.22 cm (IQR 0.10 to 0.35 cm) on nondislocated shoulders, and 3.30 cm (IQR 2.59 to 4.00 cm) in posterior dislocations.

Conclusion: A posterior approach point-of-care ultrasonographic study is a quick and accurate tool to diagnose dislocated shoulders. Ultrasonography was also able to accurately identify humeral fractures and significantly reduce the time to diagnosis from triage compared with standard radiography. [Ann Emerg Med. 2020;76:119-128.]

Please see page 120 for the Editor's Capsule Summary of this article.

Readers: click on the link to go directly to a survey in which you can provide **feedback** to *Annals* on this particular article.

A **podcast** for this article is available at www.annemergmed.com.

0196-0644/\$-see front matter

Copyright © 2020 by the American College of Emergency Physicians.

<https://doi.org/10.1016/j.annemergmed.2020.01.008>

SEE EDITORIAL, P. 129.

INTRODUCTION

Background and Importance

The anatomy of the shoulder girdle makes this joint particularly prone to injury, with shoulder dislocations representing one of the most common forms of joint dislocations.¹ Shoulder dislocations result in approximately 200,000 emergency department (ED) visits annually and

95% to 98% of all shoulder dislocations occur anteriorly.^{1,2} The conventional diagnostic pathway for a patient with presumed shoulder dislocation involves a pre- and postreduction radiograph of the shoulder.^{1,2} However, many emergency physicians have begun to challenge the current paradigm that all patients with presumed shoulder dislocations require both pre- and postreduction radiographs. Several studies illustrate that postreduction radiographs rarely detect new or clinically significant fractures.³⁻⁸

Editor's Capsule Summary*What is already known on this topic*

Early studies of bedside ultrasonography for shoulder injuries have shown generally favorable but inconsistent performance in detecting injuries.

What question this study addressed

This study examined the sensitivity and specificity of an optimized ultrasonographic imaging strategy when deployed across a variety of centers and sonographers.

What this study adds to our knowledge

Optimal ultrasonographic imaging provides a very sensitive and specific means of detecting important shoulder injuries, including dislocations and fractures.

How this is relevant to clinical practice

Ultrasonographic imaging could provide clinicians with a convenient means of quickly assessing patients with shoulder injuries.

Research we would like to see

Delineation of the optimal role of ultrasonography in the management of suspected shoulder dislocations.

Evidence suggests that bedside ultrasonography of the shoulder may be a valuable tool for diagnosing shoulder dislocation and reduction.⁹⁻¹⁹ Point-of-care ultrasonography can be performed while a patient's history is obtained and physical examination is performed, which may reduce the time to diagnosis of a shoulder dislocation. Additional benefits may include reduced radiation exposure, lower cost, and shorter length of stay for patients.^{13,19}

Previous studies have found that the accuracy of point-of-care ultrasonography for detecting shoulder dislocations is nearly 100%.¹⁹ However, these studies were limited by significant heterogeneity in regard to the techniques and patient populations.¹⁴⁻¹⁸ The anterior and lateral approaches have demonstrated variability in accuracy, with one study finding 100% specificity but only 54% sensitivity for this technique.¹⁶ The posterior approach typically involves following the humerus to the glenohumeral joint but may be limited in patients with large triceps or abnormal anatomy. This study assesses a novel approach to detecting glenohumeral dislocation by tracing the scapular spine. Because the scapular spine is more superficial than the humerus or coracoid process, this technique addresses many of the limitations of previous

techniques. Additionally, to our knowledge previous studies have not evaluated the effect of point-of-care ultrasonography on time to image acquisition, time to overall diagnosis, or the optimal glenohumeral distance to use for discriminating between dislocated and nondislocated shoulder joints.

Goals of This Investigation

The primary goal of this study was to determine the sensitivity and specificity of point-of-care ultrasonography compared with the current criterion standard of radiography in diagnosing shoulder dislocations. Secondary goals were to determine the time required for point-of-care ultrasonographic image acquisition, the optimal glenohumeral distance for discriminating anterior and posterior dislocations from a nondislocated shoulder, presence or absence of fracture, sonographer confidence, and the difference in time to diagnosis between point-of-care ultrasonography and radiography from triage.

MATERIALS AND METHODS**Study Design and Setting**

This was a multicenter, prospective, observational study at 2 academic EDs from March 2017 to May 2019. One location was a suburban university-based hospital in the Northeast with an emergency medicine residency and an annual adult ED census of 74,000 patients. The other location was an urban university-based hospital ED in the Midwest with an emergency medicine residency and an annual adult ED census of approximately 56,000 patients.

Selection of Participants

We included all adult patients (defined as ≥ 18 years) presenting to the ED for suspected shoulder dislocation when a study investigator was present. One of 6 ultrasonography fellows or fellowship-trained emergency physicians performed the study, using the modified posterior approach described later. We excluded patients with multiple traumatic injuries, with decreased level of consciousness, who were hemodynamically unstable, or who did not consent to undergo sonography. Written informed consent was obtained for all participants. The institutional review board at both institutions approved the study.

Interventions

Before patient enrollment, all providers underwent training on the technique, using a short instructional video on the study, followed by practice on actual patients. After a history and physical examination were obtained by the

treating physician, a blinded sonographer performed the bedside ultrasonography (prereduction scan) while the patient was waiting for either radiography to be performed or the results to be read by a radiologist. The sonographer was blinded to the history and imaging findings. To prevent interrupting patient care, patients remained eligible for enrollment if radiographic imaging was performed before the point-of-care ultrasonographic examination, but only if the sonographer and treating physician were not aware of the radiographic results.

If the shoulder was confirmed as dislocated on the radiograph, the treating physician was allowed to reduce the shoulder using whichever reduction technique he or she deemed appropriate. Once the reduction was performed, the sonographer repeated the shoulder point-of-care ultrasonographic examination (postreduction) to determine the location of the humeral head with respect to the glenoid. The patient also underwent postreduction radiography.

After each ultrasonographic examination (pre- and postreduction), the sonographer recorded the presence of a dislocation based on point-of-care ultrasonography, presence of a fracture based on point-of-care ultrasonography, time to perform the point-of-care ultrasonographic examination, sonographer confidence, and the time of the point-of-care ultrasonographic examination. Time to perform the point-of-care ultrasonography was assessed by an independent observer using a digital timer and recorded from the time the transducer was placed on the patient's skin to the time the diagnosis was made. Sonographers also measured and recorded the distance from the glenoid rim to the humerus (ie, the glenohumeral distance). The investigator collected all other data points from the medical record at this time.

All radiographs consisted of 3 views and were interpreted by a board-certified attending radiologist, who was blinded to the ultrasonographic results. The radiographs served as the criterion standard. All point-of-care ultrasonographic images were saved and reviewed for interrater reliability by a separate ultrasonographic fellowship-trained attending emergency physician who was blinded to the initial point-of-care ultrasonographic determinations and radiographic results.

Investigators collected data on patient age, sex, height, weight, body mass index, history of dislocations, mechanism of injury, triage time, time of the pre- and postreduction point-of-care ultrasonographic examination, time of the pre- and postreduction radiographs, location of the dislocation on point-of-care ultrasonography and radiography, presence of a fracture, type of fracture (eg, Hill-Sachs, humeral head), type of reduction technique,

duration of the point-of-care ultrasonographic examination, and glenohumeral distance. Dislocations were classified as anterior, posterior, inferior, or nondislocated for both radiographs and point-of-care ultrasonography. Dislocations described as "anterior and inferior" on radiographs were classified as anterior if there was no evidence of isolated inferior dislocation (ie, luxatio erecta) on the imaging or physical examination. This was decided because there is no clinically significant change in the clinical management and reduction technique for those cases. Fractures were further divided into categories including Hill-Sachs/Bankart's and non-Hill-Sachs/Bankart's fractures. Hill-Sachs/Bankart's fractures included Hill-Sachs's deformities (impaction fracture of the humeral head) and Bankart's lesions (avulsion of the glenoid labrum or rim). Non-Hill-Sachs/Bankart's fractures included other humeral fractures of the proximal head, neck, shaft, and greater tuberosity. Study investigators collected all data prospectively at enrollment.

The sonographer imaged the shoulder from the posterior approach in a transverse plane, with the indicator toward the sonographer's left (Figure 1A). The sonographer palpated and placed the probe over the spine of the scapula as the initial landmark (Figure 1B), and then slid the transducer laterally to identify the scapular notch and then the bony landmarks of the glenoid fossa and humeral head (Figure 1C). On identifying the glenohumeral joint, the sonographer first assessed for the presence of a dislocation. After assessing for dislocation, the sonographer fanned the transducer from a cephalic to caudal direction to determine whether a humeral head or humeral neck fracture was present (Figure 1D). A fracture would appear as an anechoic or hypoechoic disruption in the normal contour of the (hyperechoic) bone.

After determination of the presence of dislocation or fracture, the glenohumeral distance was measured¹⁵ as the vertical difference between 2 imaginary horizontal lines (Figure 2A). One horizontal line was drawn from the most posterior aspect of the humeral head (top of the humerus on ultrasonographic image) and the other horizontal line was drawn from the most posterior visible portion of the glenoid (top of the glenoid rim on the ultrasonographic image). An anterior dislocation was defined as the humeral head's being displaced anteriorly compared with the glenoid rim (Figure 2B), or farther from the transducer (ie, distal to the transducer surface), whereas a posterior dislocation was defined as the humeral head's being displaced posteriorly (Figure 2C), or closer to the transducer (ie, closer to the transducer surface) compared with the glenoid rim. Sonographers used a Mindray M9 (Mindray, Mahwah, NJ), Mindray TE7 (Mindray),

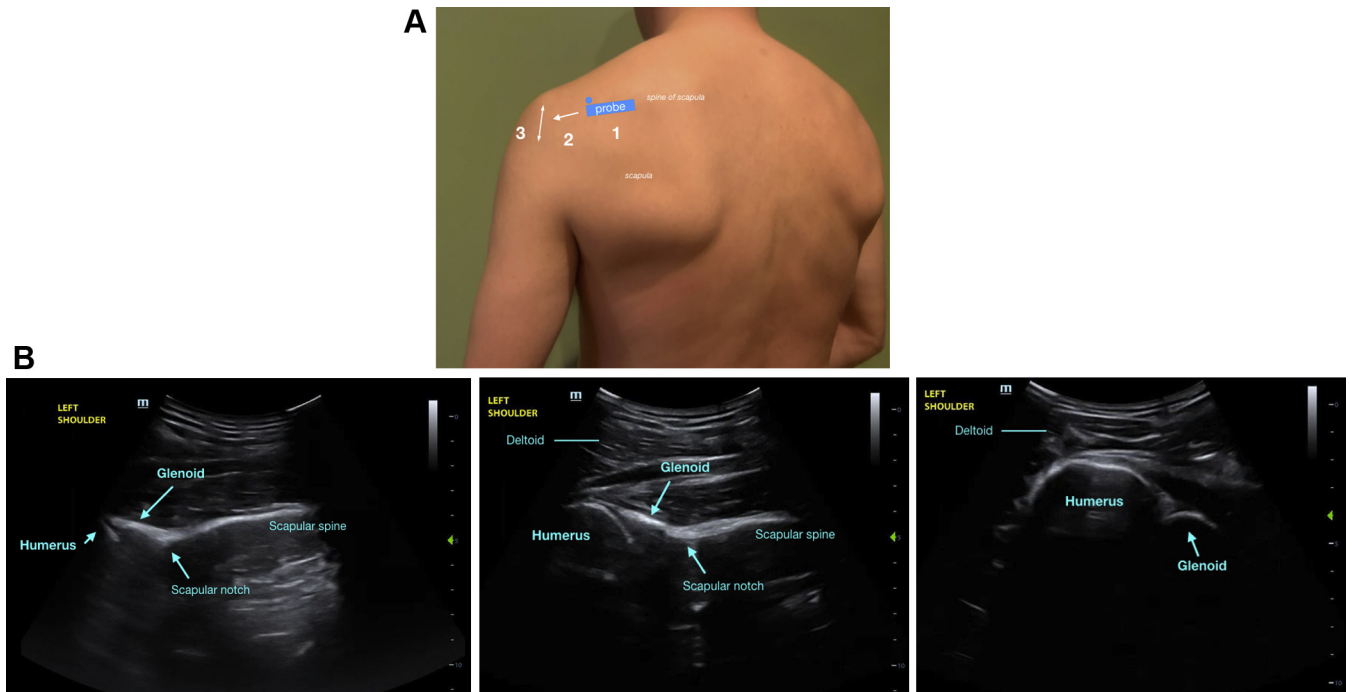


Figure 1. A, Proper probe placement on the patient and the 3-step sequence to examine the shoulder from the posterior approach. The blue dot above the probe corresponds to the probe indicator. B, The corresponding ultrasonographic images to the probe placement in A at the level of the scapular spine (1), the glenohumeral joint (2), and the humerus (3).

SonoSite Edge II (Fujifilm, Bothell, WA), or Zonare ZS-3 (Mindray) ultrasonographic machine. Selection of the transducer type (ie, linear or curvilinear) was at the sonographer's discretion.

Outcome Measures

The primary outcome was the diagnostic accuracy of the point-of-care ultrasonographic examination. Secondary outcomes were time to diagnosis from triage, length of point-of-care ultrasonographic examination, determination of glenohumeral distance of nondislocated and dislocated shoulders, presence or absence of fracture, and sonographer confidence in diagnosis, measured on a verbal numeric scale from 0 (none) to 10 (most).

Primary Data Analysis

Data are presented as medians with interquartile ranges (IQRs) for continuous variables. Frequencies are presented as percentages with 95% confidence intervals (CIs). The diagnostic accuracy of point-of-care ultrasonography in detecting shoulder dislocation and confirmation of reduction is presented by calculating sensitivity, specificity, positive predictive value, and negative predictive value compared with radiography as the criterion standard. Receiver operating characteristic (ROC) analysis with Youden's index²⁰ was used to identify the optimal

displacement cutoffs for diagnosing dislocations.

The κ coefficient was used to determine interrater reliability for diagnosing both shoulder dislocation and non-Hill-Sachs/Bankart's fractures of the humerus. With an expected sensitivity of 95% and a 95% CI of 90% to 100%, 80% power, and a 2-tailed α of .05, we estimated that a sample size of 61 subjects would be needed.

RESULTS

Sixty-five subjects were enrolled in the study. No patients were excluded. Table 1 describes the patient demographics. The median age was 40 years (IQR 27 to 61 years) and 38 (58%) of the subjects were men. The median body mass index was 27.4 kg/m² (IQR 23.7 to 31.9 kg/m²). Of the 65 enrolled patients, 21 (32%) had a history of dislocations, and 28 (43%) sustained injuries from ground-level falls.

Of the 65 patients, 32 (49%) had a shoulder dislocation. The types of dislocations and time to diagnosis from triage are described in Table 2. The numbers of ultrasonographic evaluations performed by attending physicians and active ultrasonography fellows by institution are provided in Table 3. All of the 65 patients received a correct diagnosis of a dislocation or nondislocated shoulder with point-of-care ultrasonography (Figure 3A). The sensitivity of point-of-care ultrasonography to accurately diagnose shoulder

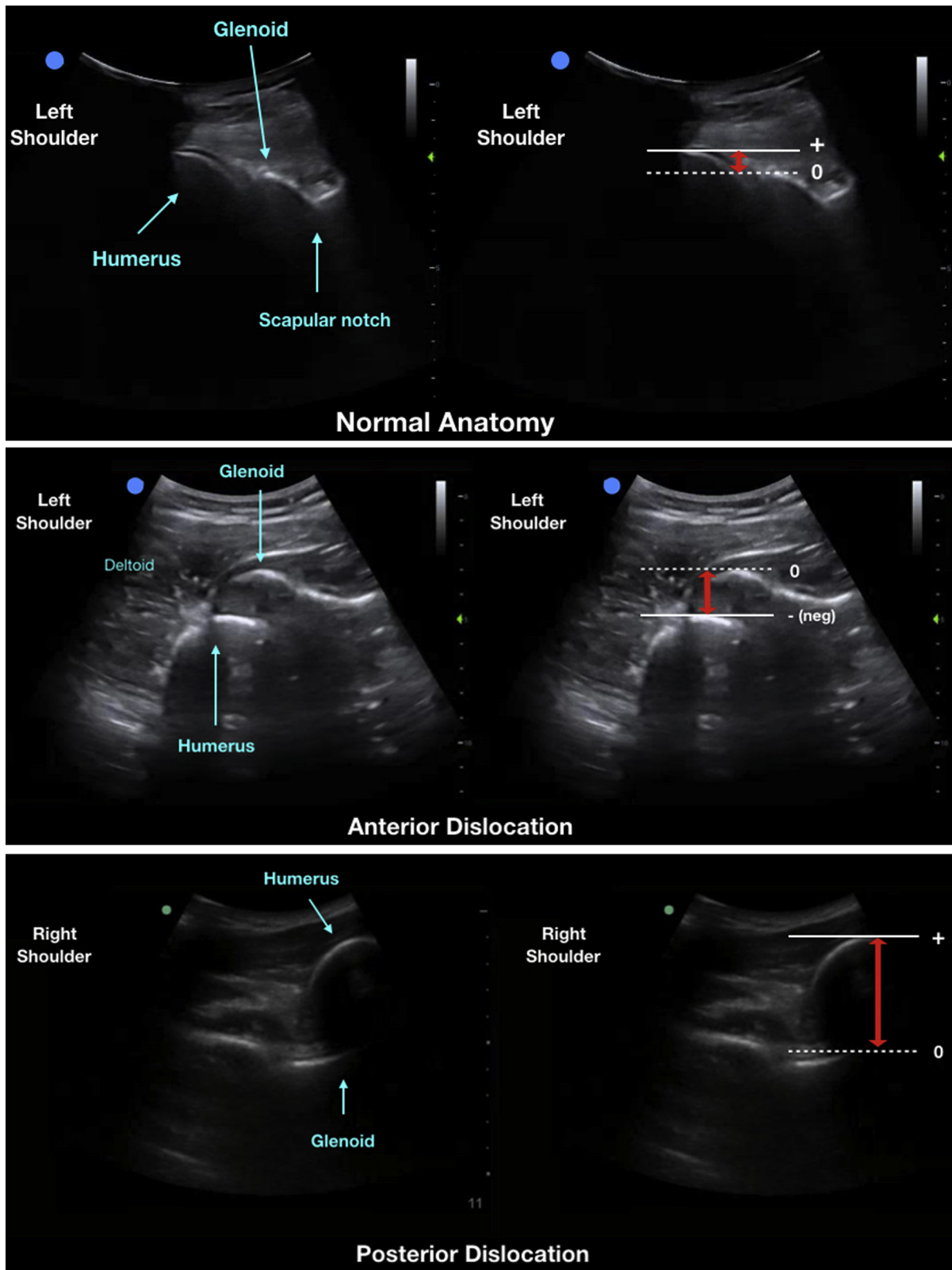


Figure 2. Ultrasonographic images of the shoulder girdle, using a curvilinear probe demonstrating the normal anatomy of the left glenohumeral joint (A), a left anterior dislocation of the shoulder with humeral head displaced anterior to the glenoid (B), and a right posterior shoulder dislocation with the humerus displaced posterior to the glenoid (C). The adjacent images correspond to the measurement of the glenohumeral distance, indicated by the red arrows.

dislocation was 100% (95% CI 87% to 100%), specificity was 100% (95% CI 87% to 100%), positive predictive value was 100% (95% CI 87% to 100%), and negative predictive value was 100% (95% CI 87% to 100%). Twenty-seven of the 32 subjects with dislocations had postreduction point-of-care ultrasonography performed and documented. Five instances of postreduction point-of-care ultrasonography were not performed because the study sonographer was unavailable after the reduction for various reasons, including other clinical or personal responsibilities. All 27 postreduction point-of-care ultrasonographic results were in agreement with the radiologic imaging about whether the reduction was successful (Figure 3B).

The median glenohumeral distance was -1.83 cm (IQR -1.98 to -1.41 cm) in anterior dislocations, 0.22 cm (IQR 0.10 to 0.35 cm) on nondislocated shoulders, and 3.30 cm (IQR 2.59 to 4.00 cm) in posterior dislocations (Figure 4). With the distance from the glenohumeral joint as the test variable and radiographic determination of dislocation as the outcome of interest, the area under the ROC curve was

Table 1. Demographics of the included patients.

Demographics	Total No.	Percentage
Sex		
Men	38	58
Women	27	42
Age, median (IQR), y	40 (27–61)	—*
Height, median (IQR), inches	68 (64–71)	—
Weight, median (IQR), lb	176 (154–200)	—
BMI, median (IQR), kg/m ²	27.4 (23.7–31.9)	—
Mechanism of injury		
Fall, ground	28	43
Fall, height	9	14
Reaching/pulling	11	17
Blunt trauma	4	6
Sports related	4	6
Lifting	3	5
Seizure	3	5
Fight	1	2
Unspecified	2	3
History of dislocation		
Yes	21	32
No	44	68
Transducer used		
Linear	12	18
Curvilinear	51	78
Both	2	3

BMI, Body mass index.

*Dashes indicate there are no percentage ranges.

Table 2. Types of dislocations and time to diagnosis.

Type of Dislocation (Radiography)	Total No.	Percentage
None	33	51
Anterior	29	45
Posterior	2	3
Inferior	1	2
Type of dislocation (POCUS)		
None	33	51
Anterior	29	45
Posterior	2	3
Inferior	1	2
Median time to POCUS from triage (IQR), min	51 (36–77)	—
Median time to radiography from triage (IQR), min	101 (73–134)	—
Median time to make the diagnosis with POCUS (IQR), s	18 (10–33)	—

POCUS, Point-of-care ultrasonography.

0.98 (95% CI 0.96 to 1.00). In accordance with Youden's index,²⁰ the optimal cutoff for the glenohumeral distance was -0.46 for anterior dislocations. This distance resulted in perfect agreement with the presence of anterior dislocation as determined with point-of-care ultrasonography, giving the same sensitivity, specificity, positive predictive value, and negative predictive value as the radiologic diagnosis of dislocation. There was an insufficient sample size to calculate an optimal cutoff value for posterior dislocations.

For the 65 patients, there were 25 (38%) total fractures identified on radiography. Of those cases, point-of-care ultrasonography identified 13 fractures (52%). Of the fractures not observed on ultrasonography, 10 were Hill-Sachs's deformities, 1 was a Bankart's lesion, and 1 was a fracture of the surgical neck. There was therefore only 1 non-Hill-Sachs/Bankart's fracture of the 12 total missed fractures. Of the total 25 fractures identified on radiography, there were 13 Hill-Sachs/Bankart's and 12 non-Hill-Sachs/

Table 3. The number of ultrasonographic examinations performed by emergency ultrasonography fellows and fellowship-trained physicians at each institution.

Institution	No. Performed by Attending Physicians (%)	No. Performed by Active Fellows (%)	Total No. Performed
1	4 (75)	1 (25)	5
2	47 (78)	13 (22)	60
Total	51 (78)	14 (22)	65

A

		X-ray	
		Dislocation	No Dislocation
US	Dislocation	32	0
	No Dislocation	0	33

B

		X-ray	
		Reduction	No Reduction
US	Reduction	27	0
	No Reduction	0	0

C

		X-ray	
		Non-HS/B Fracture	No Fracture
US	Non-HS/B Fracture	11	0
	No Fracture	1	53

Figure 3. 2×2 Tables of prerelocation ultrasonography compared with prerelocation radiography for the presence of a dislocation (A), postrelocation ultrasonography compared with postrelocation radiography for the presence of dislocation (B), and prerelocation ultrasonography compared with prerelocation radiography for the presence of non-Hill-Sachs's and Bankart's fractures (C). US, Ultrasonography; HS/B, Hill-Sachs's and Bankart's.

Bankart's fractures present. If Hill-Sachs/Bankart's deformities were excluded, point-of-care ultrasonography identified 11 of the 12 non-Hill-Sachs/Bankart's fractures of the proximal humeral head, neck, and shaft (Figure 3C). Point-of-care ultrasonography did not misidentify any false-positive non-Hill-Sachs/Bankart's fractures. Overall, point-

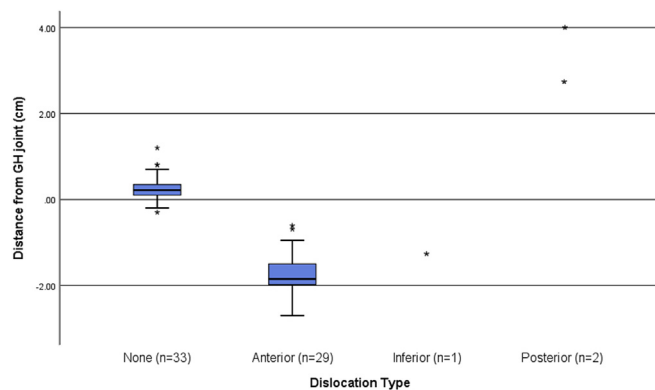


Figure 4. Box plot showing the glenohumeral distances as a function of the radiography diagnosis. GH, Glenohumeral.

of-care ultrasonography was 92% sensitive (95% CI 60% to 99.6%) and 100% specific (95% CI 92% to 100%) for non-Hill-Sachs/Bankart's fractures, with a positive predictive value of 100% (95% CI 68% to 100%) and negative predictive value of 98% (95% CI 89% to 99.9%). We had no cases of dislocations with concomitant non-Hill-Sachs/Bankart's fractures (all combined fracture-dislocations were Hill-Sachs/Bankart's deformities).

Point-of-care ultrasonography was performed earlier after triage than standard radiology in diagnosing dislocations or significant fractures (median time to performance 43 minutes; IQR 23 to 60 minutes): time to diagnosis from triage by point-of-care ultrasonography was 51 minutes (IQR 35 to 78 minutes) versus 101 minutes (IQR 73 to 134 minutes) for standard radiology. The total time required to complete the point-of-care ultrasonographic examination was 19 seconds (IQR 10 to 36 seconds). Sonographers' confidence in their point-of-care ultrasonographic diagnosis was 9.1 of 10 in nondislocated cases and 9.4 of 10 in dislocated cases.

The interrater reliability between the sonographer and the blinded reviewer was excellent. The value of κ for diagnosing dislocated shoulders was 0.97 (95% CI 0.91 to 0.99), whereas there was perfect agreement ($\kappa=1$ [95% CI 1 to 1]) for diagnosing non-Hill-Sachs/Bankart's fractures of the shoulder girdle (Figure 5A and B).

LIMITATIONS

There are several limitations to consider with respect to our study. This was a convenience study and subjects were enrolled only when trained sonographers were present. Although sonographers were present on days, nights, and weekends throughout the study period, it is likely that some patients were not enrolled because of lack of sonographer availability. We were also able to capture only 27 postrelocation ultrasonographic results from the 32 subjects with confirmed dislocations. These 5 patients were likely missed because the study sonographer was unable to stay for the length of time required to perform postprocedure ultrasonography after relocation attempts. Moreover, point-of-care ultrasonography is operator dependent. Another limitation of our study is that emergency physicians with partial or complete fellowship training in point-of-care ultrasonography are the only ones who performed the ultrasonographic examinations and we did not choose to study physicians with nonfellowship training. Therefore, it may not entirely reflect the accuracy of the general physician population. However, a previous study by Lahham et al¹⁵ found that point-of-care ultrasonography had 100% sensitivity and specificity for

A

Sonographer	Reviewer	
	No dislocation	Dislocation
No dislocation	33	1
Dislocation	0	31

(kappa = 0.97)

B

Sonographer	Reviewer	
	No fracture	Fracture
No fracture	52	0
Fracture	0	13

(kappa = 1.00)

Figure 5. 2×2 Tables of interrater agreement between sonographer versus blind reviewer for presence of dislocations (A) and interrater agreement between sonographer versus blind reviewer for presence of fractures (B).

dislocation when performed by novice sonographers. Moreover, the lack of validation of the glenohumeral distance cutoff in a separate independent population was another limitation of our study and should be considered for future studies. Also, as musculoskeletal ultrasonography becomes a more mainstream application, additional studies are necessary to determine the difference in accuracy between different provider experience levels and the ideal training protocol. Finally, we did not study or encounter patients with subluxation of the humerus and cannot extrapolate what direction and what the glenohumeral distance would be in such patients.

DISCUSSION

To our knowledge, this is the first study to assess a novel, easy-to-perform, posterior, point-of-care ultrasonographic technique for identifying shoulder dislocations and reductions, as well as the only study to assess time to perform the point-of-care ultrasonographic examination and the effect on time to diagnosis compared with radiography. Our study found 100% sensitivity and 100% specificity for the diagnosis of shoulder dislocations and reductions, with a mean point-of-care ultrasonographic examination time of 27 seconds and a 48-minute reduction in time to diagnosis compared with that for radiographs.

Previous studies have demonstrated relatively high diagnostic accuracies with point-of-care ultrasonography.¹⁴⁻¹⁸ However, the studies were limited by the use of only 1 or 2 providers at a single site,¹⁴⁻¹⁸ as well as concerns about inadequate criterion standards and blinding.¹⁶ The results of our study are also congruent with a recent systematic review and meta-analysis by Gottlieb and Russell,¹³ which demonstrated that point-of-care ultrasonography is highly accurate in diagnosing dislocated shoulders. Like most

previous studies, however, many of the studies in the systematic review and meta-analysis had very high rates of dislocations, which may have influenced the sonographers' assessment, as well as the test characteristics.¹³⁻¹⁸ Our study includes a population with a lower prevalence of dislocations (49%), which improves the test characteristics and external validity. Despite the lower percentage of patients with dislocations, sonographers in our study still had 100% sensitivity and specificity for the diagnosis of dislocations and reductions. Additionally, our study adds more patients with posterior dislocations, time to diagnosis, and point-of-care ultrasonographic performance time, which were specifically identified as a need by the systematic review and meta-analysis.

We found that the overall time to diagnosis from triage was significantly reduced with the use of point-of-care ultrasonography. On average, the time from arrival to diagnosis decreased by 48 minutes compared with that for radiographs. This can allow more rapid delivery of a targeted pain intervention (eg, nerve block, intra-articular injection, analgesia). Moreover, by faster identification of the dislocation, patients may have their shoulders reduced sooner, which can minimize the associated spasm and may make the reduction attempt easier.^{1,2} Another benefit of point-of-care ultrasonography is that it can rapidly assess for inadequate reduction among patients receiving procedural sedation, allowing the provider to rereduce the dislocation while the patient remains sedated.

To our knowledge, this study is also the first to specifically compare the glenohumeral distance between dislocated and nondislocated shoulders. Lahham et al¹⁵ performed a study assessing whether patients with a glenohumeral distance less than 0 cm had a dislocation and were able to successfully identify all dislocations. However,

they did not report the mean distances in their study, so it is unclear what the ideal threshold distance should be. Our study found that a glenohumeral distance less than -0.5 cm is the optimal cutoff for discriminating between nondislocated and anterior dislocation. For posterior dislocations, we found that they had a mean glenohumeral distance of 3.3 cm. However, the sample size was too small (2 patients) to accurately determine an optimal cutoff for posterior dislocations.

Our study showed high accuracy and excellent interrater reliability for diagnosing non-Hill-Sachs/Bankart's fractures. Point-of-care ultrasonography identified 11 of the 12 non-Hill-Sachs/Bankart's fractures, which we consider more clinically significant. The one missed non-Hill-Sachs/Bankart's fracture was a surgical neck fracture, which was missed by the initial sonographer but was identified subsequently by the blinded reviewer during secondary review of the study images. These results are also consistent with the systematic review and meta-analysis by Gottlieb et al¹⁹ showing point-of-care ultrasonography as having 97.9% sensitivity and 99.8% specificity for assessing for the presence of associated fractures.

The majority of fractures not observed on ultrasonography were either a Hill-Sachs's deformity (total of 10) or Bankart's lesion (total of 1). Hill-Sachs's deformities are common and are demonstrated in 67% to 93% of anterior dislocations.^{5,14,18,19} Multiple publications during the past 25 years have shown that Hill-Sachs's deformities are present on initial radiography and are not commonly caused by the reduction technique, and that identification does not change acute management.^{5,19} Previous studies have shown that ultrasonography is highly accurate and superior to the best radiologic views in the identification of Hill-Sachs's lesions,²¹ which is discrepant with our own results. Fracture identification was a secondary endpoint of this study because the primary goal was to establish the accuracy of point-of-care ultrasonography for shoulder dislocation. Our particular posterior technique did not allow entire visualization of the glenoid and therefore limited our ability to detect both Hill-Sachs's and Bankart's lesions. Only one Bankart's lesion was identified on radiography during our enrollment period. Although many proximal humerus fractures of all types are typically treated conservatively in the acute setting, we believe that the presence of a humeral head, neck, or shaft fracture may change management or disposition planning and is therefore more clinically significant. Hill-Sachs's deformities and Bankart's lesions may have prognostic value because they are associated with an increased risk of recurrent dislocations.^{6,22} Previous studies have, however, confirmed the inaccuracy of

radiography in identifying these lesions and suggest computed tomographic scan as the most accurate modality.²² Although patients at higher risk of recurrence may need further outpatient imaging for surgical planning, the majority of recurrent shoulder dislocations may not need any radiographic imaging in the ED. Patients at risk of persistent shoulder instability should be aware of the importance of follow-up, but to the emergency physician the presence or absence of non-Hill-Sachs/Bankart's fractures does not alter acute management, disposition, or follow-up plans.^{5,6,18,19}

An aspect of our study that makes it more generalizable is that we did not require sonographers to use a specific probe (ie, linear versus curvilinear). However, we did not believe it was acceptable to limit providers to a specific probe because the need for a specific type of probe may vary according to the anatomy and body habitus of individual patients. Our results showed no significant difference in accuracy or time to diagnosis with a particular probe in relation to patient body mass index. Anecdotally, however, the curvilinear probe has superior penetration and larger footprint on the patient, so is likely more suitable for patients with larger body mass. We therefore recommend that sonographers use their own judgment and comfort level when selecting a probe to perform posterior-approach point-of-care ultrasonography of the shoulder.

The current literature demonstrates that point-of-care ultrasonography is highly accurate in diagnosing dislocated shoulders and fractures of the humerus. Because several techniques have been described, future studies should compare the different techniques to determine which is the most accurate. Also, a study examining the accuracy of our technique in relation to novice sonographers would be valuable. It would also be essential and beneficial to validate a glenohumeral distance to accurately differentiate an anterior dislocation from subluxation from nondislocation. In addition, randomized controlled trials should be conducted to evaluate the performance of ultrasonography versus standard radiology alone at diagnosing shoulder dislocations in patients with frequent dislocations to avoid the need for pre- or postreduction radiographic imaging in this particular population. Finally, studies should evaluate what is the ideal training protocol for this modality.

Our study found that point-of-care ultrasonography from the posterior approach was a highly accurate method to diagnose shoulder dislocations. It can be performed rapidly at the patient's bedside and had a faster time to diagnosis from triage than radiography, and sonographers had high levels of confidence in their diagnoses. Point-of-care ultrasonography of the shoulder should be considered as a diagnostic option for the detection of shoulder

dislocation in the ED. Additional links can be found in Appendix E1, available online at <http://www.annemergmed.com>

The authors acknowledge Dallas Holladay, DO, for her assistance with the study.

Supervising editor: William R. Mower, MD, PhD. Specific detailed information about possible conflict of interest for individual editors is available at <https://www.annemergmed.com/editors>.

Author affiliations: From the Department of Emergency Medicine, Stony Brook University, Stony Brook, NY (Secko, Reardon, Morley, Lohse, Thode, Singer); and the Department of Emergency Medicine, Rush University Medical Center, Chicago, IL (Gottlieb).

Author contributions: MAS, LR, MG, HHT, and AJS were responsible for study design. MAS, LR, EJM, MRL, and AJS were responsible for recruitment of subjects. MAS, LR, and MRL were responsible for enrollment of subjects. MAS, MG, HHT, and AJS were responsible for data analysis. MAS, LR, and EJM were responsible for drafting the article. MAS, LR, MG, EJM, MRL, and AJS were responsible for editing the article. MG and EJM were responsible for IRB application. MAS takes responsibility for the paper as a whole.

All authors attest to meeting the four [ICMJE.org](http://www.icmje.org) authorship criteria: (1) Substantial contributions to the conception or design of the work; or the acquisition, analysis, or interpretation of data for the work; AND (2) Drafting the work or revising it critically for important intellectual content; AND (3) Final approval of the version to be published; AND (4) Agreement to be accountable for all aspects of the work in ensuring that questions related to the accuracy or integrity of any part of the work are appropriately investigated and resolved.

Funding and support: By *Annals* policy, all authors are required to disclose any and all commercial, financial, and other relationships in any way related to the subject of this article as per ICMJE conflict of interest guidelines (see www.icmje.org). The authors have stated that no such relationships exist.

Publication dates: Received for publication September 12, 2019. Revisions received November 6, 2019, and December 4, 2019. Accepted for publication January 2, 2020.

REFERENCES

- Gottlieb M. Current approach to the diagnosis and management of shoulder dislocation in children. *Pediatr Emerg Care*. 2018;34:357-364.
- Youm T, Takemoto R, Park BKH. Acute management of shoulder dislocations. *J Am Acad Orthop Surg*. 2014;22:761.
- Edmond M, Garipey C, Boucher V, et al. Selective prerelaxation radiography in anterior shoulder dislocation: the Fresno-Quebec Rule. *J Emerg Med*. 2018;55:218-225.
- Harvey RA, Trabulsky ME, Roe L. Are postreduction anteroposterior and scapular Y views useful in anterior shoulder dislocations? *Am J Emerg Med*. 1992;10:149-151.
- Hendey G, Kinlaw K. Clinically significant postreduction radiographic abnormalities in anterior shoulder dislocations. *Ann Emerg Med*. 1996;28:399-402.
- Hendey GW. Necessity of radiographs in the emergency department management of shoulder dislocations. *Ann Emerg Med*. 2000;36:108-113.
- Gottlieb M, Nakitende D, Krass L, et al. Frequency of fractures identified on post-reduction radiographs after shoulder dislocation. *West J Emerg Med*. 2016;17:35-38.
- Shuster M, Abu-Laban RB, Boyd J. Pre-reduction radiographs in clinically evident anterior dislocation. *Am J Emerg Med*. 1999;17:653-658.
- Halberg MJ, Sweeney TW, Owens WB. Bedside ultrasound for verification of shoulder reduction, a case report. *Am J Emerg Med*. 2009;27:134.e5-134.e6.
- Beck S, Chilstrom M. Point-of-care ultrasound diagnosis and treatment of posterior shoulder dislocation, a case report. *Am J Emerg Med*. 2013;31:449.e3-5.
- Mackenzie DC, Liebmann O. Point-of-care ultrasound facilitates diagnosing a posterior shoulder dislocation. *J Emerg Med*. 2013;44:976-978.
- Gottlieb M, Edwards H. Utility of ultrasound in the diagnosis of shoulder dislocation. *Emerg Med J*. 2016;33:671-672.
- Gottlieb M, Russell F. Diagnostic accuracy of ultrasound for identifying shoulder dislocations and reductions: a systematic review of the literature. *West J Emerg Med*. 2017;18:937-942.
- Abbasi S, Molaie H, Hafezimizoghadam P, et al. Diagnostic accuracy of ultrasonographic examination in the management of shoulder dislocation in the emergency department. *Ann Emerg Med*. 2013;62:170-175.
- Lahham S, Becker B, Chiem A, et al. Pilot study to determine accuracy of posterior approach ultrasound for shoulder dislocation by novice sonographers. *West J Emerg Med*. 2016;17:377-382.
- Ahmadi K, Hashemian AM, Sineh-Sepehr K, et al. Bedside ultrasonography for verification of shoulder reduction: a long way to go. *Chin J Traumatol*. 2016;19:45-48.
- Akyol C, Gungor F, Akyol AJ, et al. Point-of-care ultrasonography for the management of shoulder dislocation in ED. *Am J Emerg Med*. 2016;34:866-870.
- Seyedhosseini J, Saiidian J, Taheri AH, et al. Accuracy of point-of-care ultrasound using low frequency curvilinear transducer in the diagnosis of shoulder dislocation and confirmation of appropriate reduction. *Turk J Emerg Med*. 2017;17:132-135.
- Gottlieb M, Holladay D, Peksa GD. Point-of-care ultrasound for the diagnosis of shoulder dislocation: a systematic review and meta-analysis. *Am J Emerg Med*. 2019;37:757-761.
- Hajian-Talaki K. The choice of methods in determining the optimal cut-off value for quantitative diagnostic test evaluation. *Stat Methods Med Res*. 2018;27:2374-2383.
- Cicak N, Bilić R, Delimar D. Hill-Sachs lesion in recurrent shoulder dislocation: sonographic detection. *J Ultrasound Med*. 1998;17:557-560.
- Auffarth A, Mayer M, Kofler B, et al. The interobserver reliability in diagnosing osseous lesions after first-time anterior shoulder dislocation comparing plain radiographs with computed tomography scans. *J Shoulder Elbow Surg*. 2013;22:1507-1513.